

Applications of 3D Maxillary Dental Arch Scanning for Mathematical Prediction of Orthodontic Treatment need for Complete Unilateral Cleft Lip and Palate Patients

A. Vasiliauskas, A. Šidlauskas

*Clinic of Orthodontics, Kaunas University of Medicine,
Lukšos-Daumanto str. 6, LT-50106, Kaunas, Lithuania, phone +370 37 387560,
e-mails: vasiliauskas@kaunas.omnitel.net; antanas@kaunas.omnitel.net*

V. Šaferis

*Department of Physics, Mathematics and Biophysics, Kaunas University of Medicine
Eivenių str. 4 LT-50161, Kaunas, Lithuania, phone +370 37 327370, e-mail: viktoras.saferis@kmu.lt*

R. Adaškevičius

*Department of Ergonomics, Kaunas University of Technology, UAB “Elinvision”
Studentų str. 50, LT-51368, Kaunas, Lithuania, phone +370 37 300255, e-mail: rimas.adaskevicius@ktu.lt*

L. Linkevičienė

*Institute of Odontology, Faculty of Medicine, Vilnius University,
Žalgirio str. 115, LT-08217, Vilnius, Lithuania, phone +370 52 727589, e-mail: linklauros@gmail.com*

Introduction

Cleft lip and/or palate is the most frequently occurring congenital anomaly in the cranio-facial area. Effective treatment planning for such patients would allow them to avoid secondary deformation of dental arches and malocclusions as well as to minimize treatment time and costs. Orthodontically critical period for treatment of such patients is the mixed dentition period, when intensive growth and development of maxillo-facial system takes place. Individuals who have undergone surgical repair of a cleft lip and palate exhibit marked restriction of mid-face growth anteroposteriorly and transversally [1]. This is attributed to the restraining effect of the scar tissue.

The aim of the study was to establish the most informative morphological criteria of maxillary dental arch allowing to predict the need for orthodontic treatment and to develop the mathematical model predicting the need for orthodontic treatment of complete unilateral cleft lip and palate during the period of mixed dentition.

Description of the method

The study was based on examination of 40 patients (mean age 6.4 ± 0.4 years) with congenital non-syndromic complete unilateral cleft lip and palate according to elaborated study plan and the data collection questionnaire.

During examination of occlusion anteroposteriorly overjet was evaluated, i.e. distance between incisal edge of the upper central incisor and the labial surface of the lower central incisor was measured parallel to the occlusal plane. Dentition was regarded as normal (positive overjet) when in centric occlusion incisal edges of lower incisors occlude into the lingual surface of the upper incisors or when they are in a more distal position from the lingual surface of upper incisors. Malocclusion (negative overjet) was when incisal edges of lower incisors were ahead of the lingual surface of upper incisors. Dental arch relationship anteroposteriorly was assessed according to 5-Year-Old's Index, proposed by N. Atack and co-workers in 1997 for complete unilateral cleft lip and palate patients [2]. According to diagnostic models dental arch relationship was assessed by a 5 point scale, where 1 corresponded to an excellent outcome, and 5 – to a very poor outcome (Fig. 1) [3].

The analysis of occlusion transversally included the assessment of the relationship between dental arches in the area of second deciduous molars. Normal occlusion (no crossbite) was stated when in centric occlusion buccal cusps of lower molars fit into the intercuspal groove of respective upper molars. Malocclusion (crossbite) was considered when buccal cusps of upper molars fit into the intercuspal groove of respective lower molars. The analysis of occlusion and the form of maxillary dental arch was performed by assessment of the degree of posterior

and anterior crossbite according to Huddart and Bodenham assessment scale [4], modified by Heidbuchel (Fig. 2) [5].

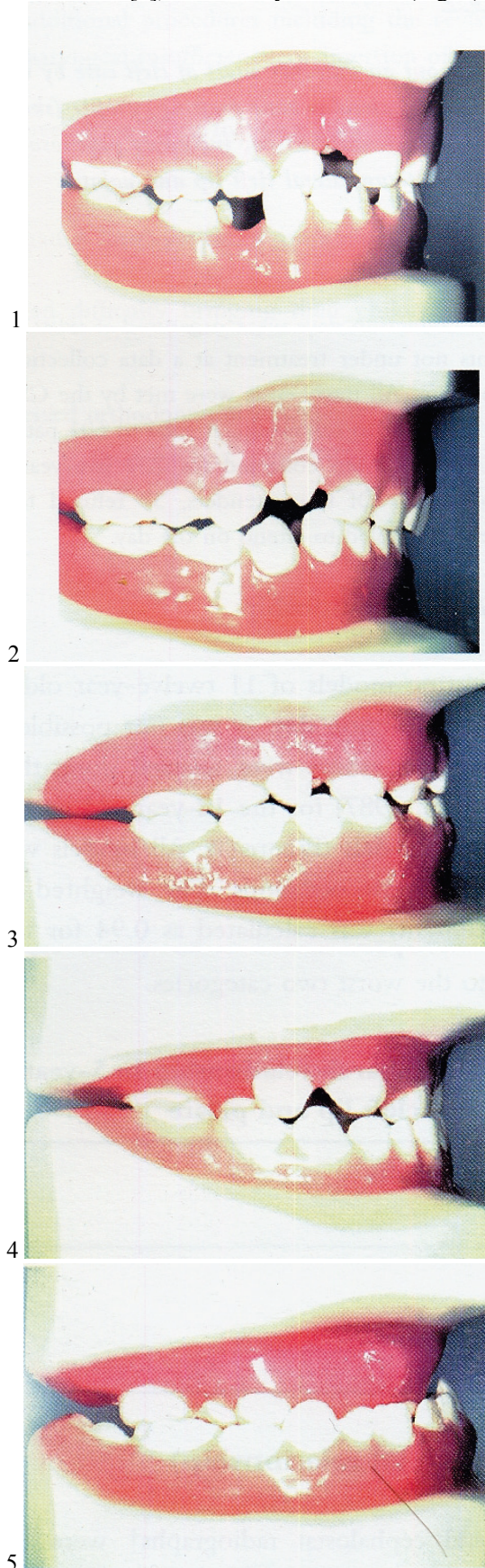


Fig. 1. Index of treatment and prognosis of 5-year-old complete unilateral cleft lip and palate patients

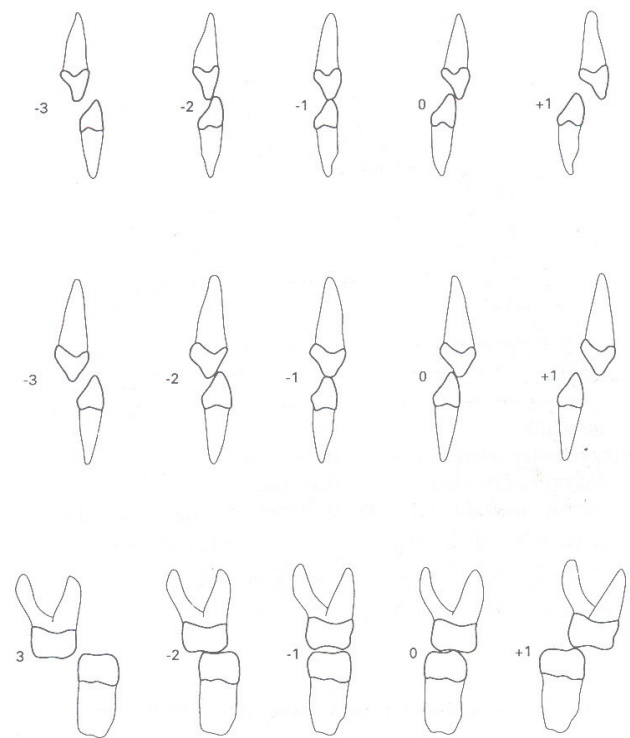


Fig. 2. Huddart's scoring of buccolingual dental relationship

In the maxillary dental arch of patients 2 buccal (cleft and noncleft sides) and one frontal segment were selected for analysis. In the buccal segments the relations of upper second deciduous molars and deciduous canines to mandibular dental arch were assessed. In the frontal segment, the relation of the upper incisors to mandibular dental arch was evaluated. According to diagnostic models, recorded in the centric occlusion, occlusion relations of dental arches were assessed by a 5-point scale, with (+1) corresponding to an excellent result, and (-3) to a very poor result.

Measurements of maxillary diagnostic models of the studied subjects were performed in 3D computerized images. The three-dimensional scanner based on the laser triangulation method was used for scanning dental casts [6, 7]. Analysis of diagnostic models included assessment of length, width of dental arches and their relationship anteroposteriorly and transversally, height of palate and the shape of maxillary dental arch.

Four auxiliary points P_1 , P_2 , P_3 and P_4 were manually captured on each dental cast 3D model to define the positions of midincisal points of the central incisors. The position of each point is selected on the incisal edge. The coordinates x , y and z of the midpoint P_{ii} of the incisor surface (Fig. 3) when these points are given by their cartesian coordinates in a 3 dimensional space are:

$$\begin{aligned} x &= \frac{x_1 + x_2}{2}, \\ y &= \frac{y_1 + y_2}{2}, \\ z &= \frac{z_1 + z_2}{2}. \end{aligned} \quad (1)$$

molars, and dental arch width in the area of the deciduous canines.

After one step convergence procedure, the only statistically significant indicator was dental arch altitude length. Other indicators were rejected by discriminant analysis procedure as statistically non-significant ($p > 0.05$).

Coefficients of Fisher's linear discriminant functions are presented in Table 1.

Table 1. Coefficients of Fisher's linear discriminant functions for prediction of orthodontic treatment need assessing occlusion anteroposteriorly

Maxillary morphological criterion	Assessment of occlusion anteroposteriorly	
	norm	anomaly
Maxillary dental arch altitude length	6,162	5,460
Constant	-84,246	-66,291

Prediction of orthodontic treatment need when assessing occlusion anteroposteriorly is presented in Table 2.

Table 2. Prediction of orthodontic treatment need when assessing occlusion anteroposteriorly

Orthodontic treatment need when assessing occlusion anteroposteriorly observed class	Orthodontic treatment need when assessing occlusion anteroposteriorly predicted class	Total
norm	n	15
anomaly	n	20
norm	%	100
anomaly	%	100

Mean effectiveness of prognosis is 77.1 percent.

For prognosis of new cases using the same method, values of discriminant functions in cases of norm (f_n) and anomaly (f_a) should be calculated:

$$\begin{aligned} f_n &= -84.246 + 6.162 * x, \\ f_a &= -66.291 + 5.460 * x, \end{aligned} \quad (4)$$

here x – maxillary dental arch altitude length.

The case then is ascribed to that class according to the need for orthodontic treatment in anteroposterior direction, which has the highest value of the function.

In order to find the optimal point in maxillary dental arch altitude length, discriminating the norm and anomaly, and reaching the highest sensitivity, while retaining the highest specificity, linear diagrams (ROC curves), reflecting sensitivity and specificity of each point were drawn. The point of concurrent curves was regarded optimal at significantly high precision of prognosis.

Finding estimates of optimal point in maxillary dental arch altitude length, discriminating the norm and anomaly is shown in the linear diagram in Fig. 5.

As we can see, the optimal point, discriminating norm and anomaly, is equal to 26.5 mm. At this point, sensitivity of maxillary dental arch altitude length is 0.80, and specificity is 0.85.

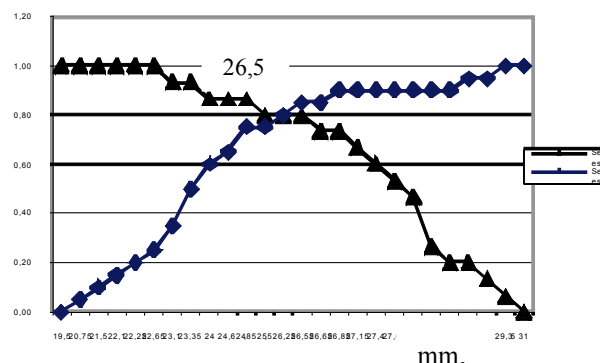


Fig. 5. Finding of optimal point in maxillary dental arch altitude length, discriminating the norm and anomaly

Accordingly, for prediction of orthodontic treatment need assessing occlusion transversally, discriminant analysis was performed according to the following maxillary morphological criteria: dental arch width in the area of second deciduous molars, dental arch altitude length, the height of palate in the area of second deciduous molars, and dental arch width in the area of the deciduous canines.

After one step convergence procedure, the only statistically significant indicator was dental arch width in the area of second deciduous molars. Other indicators were rejected by discriminant analysis procedure as statistically non-significant ($p > 0.05$).

Coefficients of Fisher's linear discriminant functions are presented in Table 3.

Table 3. Coefficients of Fisher's linear discriminant functions for prediction of orthodontic treatment need assessing occlusion transversally

Maxillary morphological criterion	Assessment of occlusion transversally	
	norm	anomaly
Maxillary dental arch width in the area of second deciduous molars	8,297	7,729
Constant	-152,358	-132,289

Prediction of orthodontic treatment when assessing occlusion transversally is presented in Table 4.

Table 4. Prediction of orthodontic treatment need when assessing occlusion transversally

Orthodontic treatment need when assessing occlusion transversally observed class	Orthodontic treatment need when assessing occlusion transversally predicted class	Total
norm	n	14
anomaly	n	19
norm	%	100
anomaly	%	100

Mean effectiveness of prognosis is 78.8 percent.

For prognosis of new cases using the same method, values of discriminant functions in cases of norm (f'_n) and abnormality (f'_a) should be calculated:

$$\begin{aligned} f'_n &= -152.358 + 8.297 * x', \\ f'_a &= -132.289 + 7.729 * x', \end{aligned} \quad (5)$$

here x' – maxillary dental arch width in the area of second deciduous molars.

The case then is ascribed to that class according to the need for orthodontic treatment transversally, which has the highest value of the function.

In order to find the optimal point in maxillary dental arch width in the area of secondary deciduous molars, discriminating the norm and anomaly and reaching the highest sensitivity, while retaining the highest specificity, linear diagrams (ROC curves), reflecting sensitivity and specificity of each point were drawn.

Finding estimates of optimal point in maxillary dental arch width in the area of secondary deciduous molars, discriminating the norm and abnormality in transversal direction is shown in the linear diagram in Fig. 6.

As we can see, the optimal point, discriminating norm and abnormality, is equal to 36.3 mm. At this point, sensitivity of maxillary dental arch width in the area of secondary deciduous molars is 0.84, and specificity is 0.79.

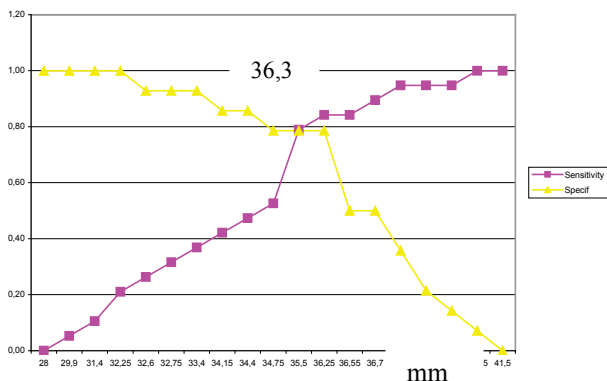


Fig. 6. Finding of optimal point in maxillary dental arch width in the area of secondary deciduous molars, discriminating the norm and anomaly

Assessment of the treatment outcomes of congenital cleft lip and palate is especially difficult due to scarce prevalence and complex care. Final decisions regarding the treatment outcome in this anomaly is possible after long-term follow up only.

Conclusions

1. The length of maxillary dental arch altitude proved to be the most credible morphological criterion for evaluation of occlusion anteroposteriorly (77.1 percent prognostic value) in children with complete unilateral

cleft lip and palate in order to predict orthodontic treatment need during the period of the early mixed dentition.

2. The width of maxillary dental arch in the area of second primary molars proved to be the most credible morphological criterion for evaluation of occlusion transversally (77.8 percent prognostic value) in children with complete unilateral cleft lip and palate in order to predict orthodontic treatment need during the period of mixed dentition.
3. Long-term follow up is required in order to confirm effectiveness of cleft care.

Acknowledgement

The study was partially funded by the Lithuanian State Science and Studies Foundation project “Investigation of genetic and genomic basis of cleft lip and/or palate (GENOLOG)” No.C-0702

References

1. **Friede H., Enemark H.** Long-term evidence for favorable midfacial growth after delayed hard palate repair in UCLP patients // *Cleft Palate-Craniofacial Journal*. – 2001. – Vol.38. – P.323–329.
2. **Atack N. E., Hathorn I. S., Mars M.** Study models of 5 year old children as predictors of surgical outcome in unilateral cleft lip and palate // *European Journal of Orthodontics* – 1997. – Vol. 19. – P.165–170.
3. **Atack N. E., Hathorn I. S., Semb G. et al.** A new index for assessing surgical outcome in unilateral cleft lip palate subjects aged five: reproducibility and validity // *Cleft Palate-Craniofacial Journal*. – 1997. – Vol.34. – P.242–245.
4. **Huddart A. G., Bodenham R. S.** The evaluation of arch form and occlusion in unilateral clefts of the lip and palate // *Cleft Palate Journal*. – 1972. – Vol.9. – P.194–209.
5. **Heidbuchel K. L. W. M.** Bilateral cleft lip and palate maxillo-facial growth and dental development. – Acco Leuven, 1997. – P. 13–23.
6. **Adaškevičius R., Vasiliauskas A.** 3D multicamera dental cast scanning system // *Electronics and Electrical Engineering*. – Kaunas: Technologija, 2008. –No. 2(82). – P. 49–52.
7. **Adaškevičius R., Vasiliauskas A.** Evaluation of Dental Arch Form Using 3D Dental Cast Scanning Technology // *Electronics and Electrical Engineering*. – Kaunas: Technologija, 2009. –No. 5(93). – P.99–102.
8. **Jolliffe I. T.** *Principal Component Analysis*, Series: Springer Series in Statistics, 2nd ed. – Springer, NY. – 2002. – 487 p.

Received 2010 02 15

A. Vasiliauskas, A. Šidlauskas, V. Šaferis, R. Adaškevičius, L. Linkevičienė. Applications of 3D Maxillary Dental Arch Scanning for Mathematical Prediction of Orthodontic Treatment need for Complete Unilateral Cleft Lip and Palate Patients // *Electronics and Electrical Engineering*. – Kaunas: Technologija, 2010. – No. 4(100). – P. 107–112.

The aim of study was to determine the most informative morphological criteria of maxillary dental arch for mathematical prediction of orthodontic treatment need for complete unilateral cleft lip and palate patients. Study was based on examination of 40 patients (mean age 6.4±0.4 years) with congenital non-syndromic complete unilateral cleft lip and palate according to elaborated study plan. Measurements of maxillary diagnostic models of the studied subjects were performed in 3D computerized images. The three-dimensional scanner based on the laser triangulation method was used for scanning dental casts. Analysis of diagnostic models included assessment of length, width of dental arches and their relationship anteroposteriorly and transversally, height of palate and the shape of maxillary dental arch. Dental arch relationship anteroposteriorly was assessed according to 5 – Year-Old Index for complete unilateral cleft lip and palate patients. The analysis of occlusion and the form of maxillary dental arch was performed by assessment of the degree

of posterior and anterior crossbite. Discriminant analysis was performed by using statistical analysis software SPSS 16. The length of maxillary dental arch altitude proved to be the most credible morphological criterion for evaluation of occlusion anteroposteriorly (77.1 percent prognostic value) in children with complete unilateral cleft lip and palate in order to predict orthodontic treatment need during the period of early mixed dentition. The width of maxillary dental arch in the area of second primary molars proved to be the most credible morphological criterion for evaluation of occlusion transversally (77.8 percent prognostic value) in children with complete unilateral cleft lip and palate in order to predict orthodontic treatment need during the period of mixed dentition. Long-term follow up is required in order to confirm effectiveness of cleft care. Ill. 6, bibl. 8, tabl. 4 (in English; abstracts in English, Russian and Lithuanian).

A. Vasiljauskas, A. Šidlauskas, V. Šaferis, R. Adaškavičius, L. Linkavičienė. Использование трехмерного сканирования верхней челюсти для математического прогнозирования потребности ортодонтического лечения больных с полным односторонним несращением верхней губы, альвеолярного отростка верхней челюсти и неба // Электроника и электротехника. – Каунас: Технология, 2010. – № 4(100). – С. 107–112.

Цель работы – установить наиболее информативные морфологические критерии верхней челюсти для прогнозирования потребности ортодонтического лечения пациентам с полным односторонним несращением верхней губы, альвеолярного отростка верхней челюсти и неба в раннем периоде сменного прикуса. Анализированы данные 40 пациентов (средний возраст – $6,4 \pm 0,4$ лет) с несиндромным врожденным полным односторонним несращением верхней губы, альвеолярного отростка верхней челюсти и неба. Измерения верхней челюсти произведены на диагностических цифровых трехмерных моделях, полученных сканированием трехмерным сканером, основанным на методе лазерной триангуляции. На диагностических моделях оценивали длину и ширину зубных рядов, прикус в сагиттальном и трансверзальном направлениях, глубину небного свода и форму зубных рядов верхней челюсти. Прикус в сагиттальном направлении оценивали по индексу результата и прогноза лечения для детей пятилетнего возраста с полным односторонним несращением верхней губы, альвеолярного отростка верхней челюсти и неба. Анализ прикуса и формы зубных рядов верхней челюсти был произведен по степени перекрестного прикуса боковых и передних зубов. Установлено, что длина зубного ряда верхней челюсти является единственным статистически значимым морфологическим критерием для прогнозирования потребности ортодонтического лечения оценивая прикус в сагиттальном направлении (среднее эффективность прогнозирования 77,1%) детям с полным односторонним несращением верхней губы, альвеолярного отростка верхней челюсти и неба в раннем периоде сменного прикуса. Ширина зубного ряда между вторыми молочными молярами является единственным статистически значимым морфологическим критерием для прогнозирования потребности ортодонтического лечения оценивая прикус в трансверзальном направлении (среднее эффективность прогнозирования 78,8%) детям с полным односторонним несращением верхней губы, альвеолярного отростка верхней челюсти и неба в раннем периоде сменного прикуса. Ил. 6, bibl. 8, табл. 4 (на английском языке; рефераты на английском, русском и литовском яз.).

A. Vasiliauskas, A. Šidlauskas, V. Šaferis, R. Adaškevičius, L. Linkevičienė. Matematinis ligonių su visiška vienpuse viršutinės lūpos, viršutinio žandikaulio alveolinės ataugos ir gomurio nesąauga ortodontinio gydymo reikalingumo prognozavimas erdviu viršutinio žandikaulio dantų lanko skenavimu // Elektronika ir elektrotechnika. – Kaunas: Technologija, 2010. – Nr. 4(100). – P. 107–112.

Darbo tikslas buvo atrinkti informatyviausius viršutinio žandikaulio morfologinius kriterijus, padedančius numatyti, ar reikalingas ortodontinis gydymas pacientams su visiška vienpuse viršutinės lūpos, viršutinio žandikaulio alveolinės ataugos ir gomurio nesąauga ankstyvojo mišriojo sąkandžio laikotarpiu. Tyrimo medžiagą sudarė 40 pacientų (amžiaus vidurkis – $6,4 \pm 0,4$ m.) su nesindromine įgimta visiška vienpuse viršutinės lūpos, viršutinio žandikaulio alveolinės ataugos ir gomurio nesąauga. Tirtąją kontingentą viršutinio žandikaulio matavimai atlikti naudojant diagnostinius kompiuterinius modelius, gautus skenuojant erdviu skeneriu, kurio veikimas paremtas lazerio trianuliacijos metodu. Diagnostinių modelių analizės metu vertintas dantų lankų ilgis, plotis, santykis sagitaline ir transversaline kryptimis, gomurio aukštis ir viršutinio žandikaulio dantų lanko forma. Dantų lankų santykis sagitaline kryptimi vertintas pagal penkiamečių, pacientų su visiška vienpuse viršutinės lūpos, viršutinio žandikaulio alveolinės ataugos ir gomurio nesąauga gydymo rezultato ir prognozės indeksą. Sąkandžio ir viršutinio žandikaulio dantų lanko formos analizė atlikta vertinant kryžminio sąkandžio laipsnį šoninių ir priekinių dantų srityje. Išeičiai prognozuoti pagal matavimo požymių reikšmes naudota diskriminantinė analizė, atlikta programų paketu SPSS 16. Tyrimo metu nustatyta, kad viršutinio žandikaulio dantų lanko aukštinės ilgis yra vienintelis statistiškai reikšmingas morfologinis kriterijus ortodontinio gydymo reikalingumui prognozuoti, vertinant vaikų su visiška vienpuse viršutinės lūpos, viršutinio žandikaulio alveolinės ataugos, gomurio nesąauga sąkandį sagitaline kryptimi (vidutinis prognozavimo efektyvumas 77,1 %) ankstyvojo mišriojo sąkandžio laikotarpiu. Viršutinio žandikaulio dantų lanko plotis antrųjų pieninių krūminių dantų srityje yra vienintelis statistiškai reikšmingas morfologinis kriterijus vaikų su visiška vienpuse viršutinės lūpos, viršutinio žandikaulio alveolinės ataugos, gomurio nesąauga ortodontiniam gydymui prognozuoti, vertinant sąkandį transversaline kryptimi (vidutinis prognozavimo efektyvumas 78,8 %) ankstyvojo mišriojo sąkandžio laikotarpiu. Pacientams su nesąauga būtina nuolatini specializuota priežiūra nuo anomalijos diagnozavimo iki kompleksinio gydymo pabaigos. Il. 6, bibl.8, lent. 4 (anglų kalba; santraukos anglų, rusų ir lietuvių k.).

DOI: 10.5755/j02.eie.9891