

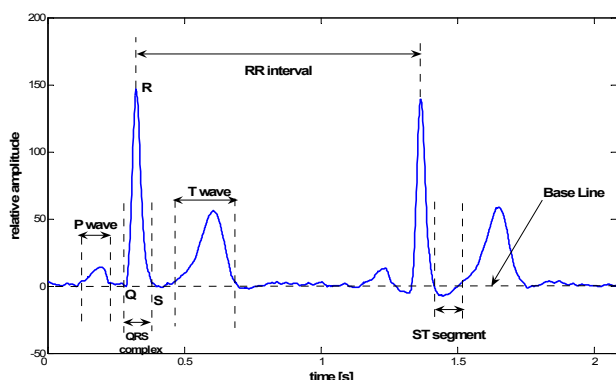
## Detection of the Left Bundle Branch Block in Continuous Wavelet Transform of ECG Signal

**Siniša S. Ilić**

*Department of General Electrical Engineering, Faculty of Technical Sciences in Kosovska Mitrovica, Knjaza Miloša 7, 28000 Kosovska Mitrovica, Serbia, tel.: +381 64 1794980, email:siniasilic@yahoo.com*

### Introduction

Electrocardiogram (ECG) is very useful in diagnosing cardiac diseases. The rules for interpreting the ECG were introduced by Einthoven a long time ago. The typical waveform of one period of an ECG signal with characteristic marks is presented in Fig. 1.



**Fig. 1.** Typical ECG waveform of healthy patient

Depending on the width and shape of QRS complex, shape of P and T wave, duration of the ECG period, position of the line of ST segment against the base line (if it is above or below the base line) in predefined ECG leads, the cardiologist can obtain different diagnoses. The typical ECG waveform of a healthy patient in D1, D2, D3, avL, avF, V4, V5 and V6 leads consists of small positive P wave, large R spike and small negative S spike and positive T wave, whose amplitude isn't greater than the amplitude of the R spike. The waveform of the avR lead should have a small negative P wave, large S spike and negative T wave. The negative S spike is the greatest in V1 lead, and its amplitude decreases as R spike amplitude increases going from V1 lead toward V3 lead. In the aforementioned three leads, P wave should be small and positive and T wave should also be positive. The ST segment should be very close to the base line in all leads, and the width of QRS complex must be less than 0.1s.

Typical waveform for Left Bundle Branch Block (LBBB) comprises of RR' teeth (consisting of two positive peaks in QRS complex, unlike the single one in a normal case), and width of QRS complex greater than 0.12s in the following ECG leads: D1, avL, V5 and V6 (complete LBBB). The same diagnosis might be obtained if there are no RR' teeth, but only one wide R spike within the QRS complex with depression of ST segment (the amplitude of the segment is below base line) with width of QRS complex about 0.12s (incomplete LBBB) [1].

A similar diagnosis can be established for Right Bundle Branch Block (RBBB), the difference is that previously mentioned shapes and widths appear mostly in D2, D3, V1 and V2 leads (behavior in V1 being the most important).

The use of Continuous Wavelet Transform (CWT) is frequently used in interpreting segments of ECG signal. Some authors [2] have used the CWT to show and detect fetal heart signals during pregnancy. CWT is also used to detect QRS complex using Klauder wavelets [3] and to perform real-time analysis of the Ventricular Fibrillation Waveform [4]. The frequency of Ventricular Fibrillation is very high and it can be seen clearly by observing peaks in CWT diagram, whose positions are at high frequencies.

CWT color diagram is used also to show differences between ECG signals of patients with and without "Q" Myocardial Infarction [5]. Sometimes it is not enough to perform CWT analysis of each ECG lead. Wavelet decomposition of averaged vector magnitude of ECG signal  $W_m = \sqrt{W_x^2 + W_y^2 + W_z^2}$ , where  $W_x$ ,  $W_y$  and  $W_z$  are samples from ECG signal of three averaged orthogonal leads, as performed in [6].

### Continuous Wavelet Transform

The wavelet transform enables time-frequency representations of the signal, all with different resolutions: high resolution in time and low resolution in frequency for high frequencies and low resolution in time and high in frequency for low frequencies. The CWT does this by

having a variable window width, which is related to the scale of observation.

Any signal  $f(t)$  can be decomposed into a set of base functions  $\psi_{s,\tau}(t)$ , called the wavelets. The Continuous Wavelet Transform is obtained by formula [7]:

$$\gamma(s, \tau) = \int_{-\infty}^{\infty} f(t) \psi_{s,\tau}^*(t) dt, \quad (1)$$

where \* denotes complex conjugation. The variables  $s$  and  $\tau$  denotes scale and translation. The wavelets are generated from a single base wavelet  $\psi$ , the so-called mother wavelet, by scaling and translation:

$$\psi_{s,\tau}(t) = \frac{1}{\sqrt{s}} \psi\left(\frac{t-\tau}{s}\right). \quad (2)$$

In equation (2)  $s$  is the scale factor,  $\tau$  is translation factor and the factor  $\sqrt{s}$  is for energy normalization across different scales. Generally speaking  $\gamma_{s,\tau}(t)$  is obtained by the following process: the basic wavelet (with scale  $s = 1$ ) is shifted along the signal  $f(t)$  and for each value of time shifting  $\tau$  the integral (1) is computed, then the wavelet window is stretched by factor  $s$  (the width of the wavelet window is increased  $s$  times) and again shifted along the signal. This process can be repeated over and over again. The larger the scale, the lower frequency components that are treated.

The advantage of CWT over other time-frequency transformations is that the CWT is not limited to using sinusoidal analyzing functions. Rather, a large selection of localized waveforms can be employed as long as they satisfy predefined mathematical criteria [7].

Coefficients of the CWT are denoted as  $\gamma(s, \tau)$  for particular scale ( $s$ ) and translation ( $\tau$ ). Scale can be treated as frequency, and translation as time, but considering that larger scales represent the lower frequencies. The pseudo-frequency is a term which describes the relationship between scale and frequency, and it presents broad sense for frequencies that exist in a signal. A method to obtain pseudo-frequency is to compute central frequency  $F_c$  of the wavelet and to use the following relationship [8]:

$$F_a = \frac{F_c}{a \cdot \Delta}, \quad (3)$$

where

- $a$  is a scale,
- $\Delta$  is the sampling period,
- $F_c$  is the center frequency of a wavelet in Hz,
- $F_a$  is the pseudo - frequency corresponding to the scale  $a$  in Hz.

## Materials and methods

The ECG signal in this paper is recorded using the PC-based system for electrocardiography and data acquisition made by the author [9]. The hardware module consists of: differential multiplexers for switching between the leads, Goldberger Willson resistor network,

instrumentational amplifier and PIC microprocessor for A/D conversion and communication with PC through the standard USB port. The PC software module has a very intuitive GUI with database support where waveforms of 12 ECG leads and patient data with diagnosis can be stored. The database of ECG waveforms of about 150 patients, using PC-based ECG device is created at the Institute for emergency medicine in the city of Belgrade. Cardiologists made diagnoses for all waveforms in the database, and ECG signals with diagnosis of healthy patients and patients with LBBB are used in this study. In order to be clear to non experts about how the diagnosis is made, the software of ECG device allows the cardiologist to enter parameters to describe each segment of ECG signal.

There were 10 patients with LBBB diagnosis in the database: 4 of them had complete LBBB and 6 of them incomplete LBBB. The diagnosis of LBBB is selected because of the large width of QRS complex.

The ECG signal is sampled at a sampling frequency of 960Hz with 10 bit A/D conversion. For each of the 12 ECG leads, the signal is recorded in intervals of 6 seconds.

The Short Time Fourier Transform (STFT) diagram was first used to find differences between time frequency representations of healthy patients and patients with LBBB. But, in order to obtain good frequency resolution to observe the frequencies where the peaks of STFT coefficients occur, the length of STFT window becomes too large. Thus the resolution in the time axis is bad, and it is very hard to distinguish where basic segments of ECG signal start and stop.

According to the experience of the authors in the papers cited above, the real valued Morlet wavelet is selected for CWT in order to isolate peaks and to distinguish positive and negative changes in the waveform [10].

For the Morlet wavelet, the central frequency is  $F_c=0.8125$ . The CWT coefficients are calculated for the range of scales 8 - 512. According to the formula in equation (3) pseudo - frequencies calculated are in the range from 1.5234Hz for scale  $s = 512$  to 97,5Hz for scale  $s = 8$ .

CWT diagrams have three axes: time translation, pseudo-frequency and the amplitude of CWT coefficients  $\gamma_{s,\tau}(t)$ , where the third axis is represented in color. In the analysis of ECG signal logarithmic pseudo-frequency axis is used.

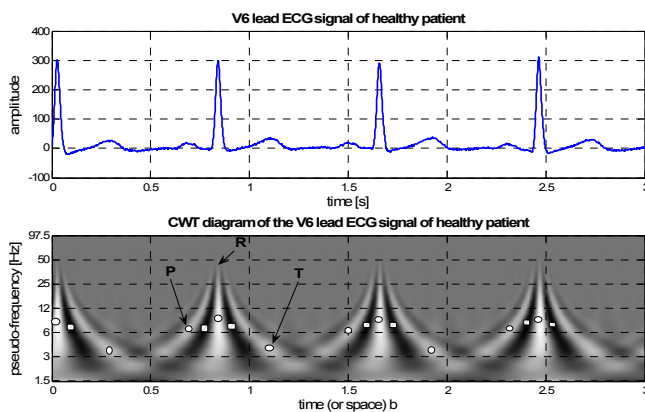
The palette of colors which represent amplitude of CWT coefficients is very similar to the palette used in geographic maps - from green through yellow and brown to red for positive amplitudes, and from light blue to dark blue for negative amplitudes. In order to comply with the constraint of printing this paper in B/W technology, shades of gray are used in the figures. The maximum values in the diagrams are depicted with small circles (for positive peaks) and small squares (for negative peaks).

## Results and discussion

The ECG waveforms of the V6 lead and appropriate CWT diagrams are presented in Fig. 2., Fig. 3. and Fig. 4.

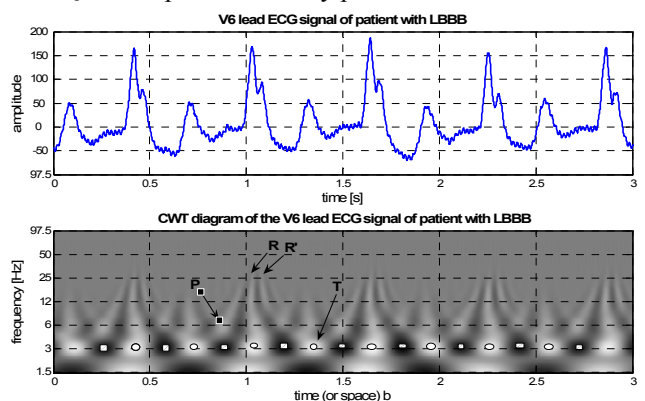
It can be seen in Fig. 2. that for a healthy patient, waveform of the V6 lead ECG signal consists of clear P wave, sharp and high positive QRS complex and clear T wave. In CWT diagram of the healthy ECG signal one can observe P wave with peak in pseudo frequency of 6-7 Hz, very high peak of QRS complex in pseudo-frequency of 8 – 9 Hz with tails which can be seen up to over 50 Hz. Position of the peak of T segment is at frequency about 4 Hz. These pseudo-frequencies tell us about the widths of P and T waves and QRS complex.

The shorter the width of the segments, the higher are the pseudo-frequencies. Also, it can be seen from the diagram of the figure Fig. 2. that concentration of the high amplitudes of CWT coefficients (bright lines) for P and T waves extend continuously from marked peaks (7 and 4 Hz respectively) up to the vicinity of denoted R spike (50 Hz).



**Fig.2.** The waveform and CWT of V6 lead ECG signal of healthy patient

In the figure Fig. 3. there is an interference of ECG signal from the public power network frequency of 50Hz, so it is very hard to detect the existence and the position of the P wave. This interference can be removed using the band stop filter, but it is left in order to show that it does not impact on main parts of CWT of ECG signal. It is very clear in ECG signal waveform that QRS complex consists of two R peaks (Rr'), where the first one is higher (R) and the second one is lower (r') in amplitude. There is a huge depression of ST segment after QRS complex, and there is a clear T wave. It can be seen in CWT diagram that P wave exists at pseudo-frequency of 6Hz, and the peak of QRS complex is at 3 Hz. It shows that QRS complex is wider than QRS complex for healthy patient.



**Fig. 3.** The waveform and CWT of V6 lead ECG signal of patient with complete Left Bundle Branch Block

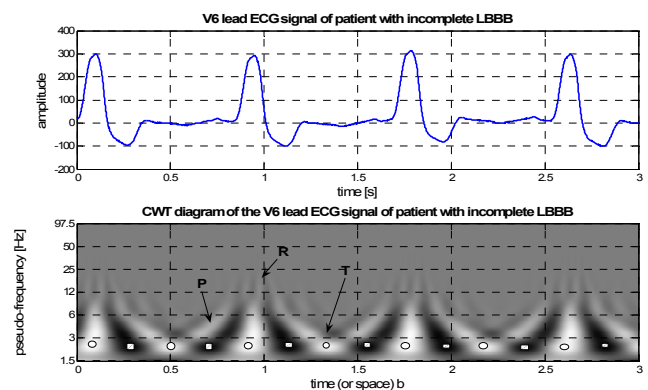
In the pseudo-frequencies of about 25-30 Hz there are more bright lines which show the existence of RR'. T wave's position is at 3 Hz, and it means that the width of T wave is almost the same as for QRS complex. This wave is isolated in CWT diagram, and there is no continuous bright line which connects T wave peak with lines in vicinity of RR' complex at 25-30 Hz.

It shows that depression of ST segment (dark area) is between QRS complex and T wave.

By carefully observation of Fig.3. one can see the sequence of the darker and lighter stripes in the vicinity of 50Hz which show the interference of public power frequency.

The waveform in Fig. 4. consists of P wave with small amplitude, wide and with a high amplitude R spike and biphasic small T wave.

One can clearly see depression of ST segment after R spike. On the CWT diagram the P wave can be seen at pseudo frequency of 3-4 Hz, R spike at 2 Hz and combination of bright and dark colors for T wave from 2-4Hz respectively. The maximum frequencies which can be observed in the diagram are up to 25 Hz.



**Fig.4.** The waveform and CWT of V6 lead ECG signal of patient with incomplete Left Bundle Branch Block

By comparing amplitudes of CWT diagram at vicinity of 1.5 Hz, it is clear that high energies are present in ECG signals with LBBB, because QRS complexes, depressions of ST segment and T waves are very wide and with high amplitudes. Hence the correlation between wavelet of high width and these segments is high. For healthy patient P and T waves are not so wide and their amplitude is small, and width of QRS complex is small, and this is the reason the energy of the signal at low frequencies is low.

## Conclusions

CWT diagrams of healthy patients and patients with LBBB are easy to distinguish. The concentration of CWT coefficients with higher amplitudes is at lower frequencies for patients with LBBB compared to healthy patients. The sequence of segments in the ECG signal can be identified in CWT diagrams too. The process of obtaining the diagnosis is easier by simultaneously studying the ECG waveform and CWT diagram.

As results show, some details are presented clearly in the time-frequency domain, which cannot be clearly

identified in the waveform. Probably, correlation between specific ECG waveforms and carefully chosen wavelets can be higher, and it may result in better recognition of characteristic segments in ECG signal.

But, it is impossible to obtain the diagnosis based on only the CWT diagram of the ECG signal.

## References

1. **Dubin D. D.** Rapid Interpretation of EKG's. – Tampa, Florida: COVER Publishing Company. – 1974.
2. **Mochimaru F., Fujimoto Y.** Detecting the fetal electrocardiogram by wavelet theory-based methods // Progress in Biomedical Research. – Vol. 7. – No. 3, 2002. – P. 185–193.
3. **Ravier P., Buttelli O.** Robust detection of QRS complex using Klauder wavelets // Proc. of XII European Signal Processing Conference (EUSIPCO-2004). – Vienna (Austria), 2004.
4. **Addison P., Watson J., Clegg G., Holzer M., Sterz F., and Robertson C.** Evaluating arrhythmias in ECG signals using wavelet transforms // IEEE Engineering in Medicine and Biology. – Vol. September/October, 2000. – P. 104–109.
5. **Tsutsumi T., Wakatsuki D., Shimojima H., Higashi Y., and Takeyama Y.** Analyzing time-frequency power spectrum limited in QRS complex based on the wavelet transform // International Journal of Bioelectromagnetism. – Vol. 6. – No.1, 2004.
6. **Yi G., Hnatkova K., Mahon N. G., Keeling P. J., Reardon M., Camm A. J., and Malik M.** Predictive value of wavelet decomposition of the signal-averaged electrocardiogram in idiopathic dilated cardiomyopathy // European Heart Journal. – Vol. 21, 2000. – P.1015–1022.
7. **Addison P. S.** Wavelet transforms and the eeg: a review // Physiological Measurement. – Vol. 26. – 2005. – P. R155–R199.
8. **Misiti M., Misiti Y., Oppenheim G., and Poggi J.** Wavelet Toolbox For use with MATLAB. – Natick, MA: The Matworks, Inc. – 2004.
9. **Žorić A. and Ilić S.** PC-based system for electrocardiography and data acquisition // Proc. of 7<sup>th</sup> International Conference on Telecommunications in Modern Satellite, Cable and Broadcasting Services TELSIKS. – Niš, Serbia and Montenegro, 2005.
10. **Torrence C. and Compo G.** A practical guide to wavelet analysis. – Bulletin of the American Metrological Society. – Vol. 79. – No.1, 1998. – P. 61–78.

Submitted for publication 2007 01 02

### **Siniša S. Ilić. Detection of the Left Bundle Branch Block in Continuous Wavelet Transform of ECG Signal // Electronics and Electrical Engineering. – Kaunas: Technologija, 2007. – No. 2(74). – P. 13–16.**

The shapes of wavelet transform of QRS complex in ECG signal for healthy patient and for patient with Left Bundle Branch Block (LBBB) are presented. The Continuous Wavelet Transform (CWT) is used with Morlet wavelet to analyze signals in Time-Frequency domain. In order to present results, CWT diagram is drawn using linear axis for translation in time and logarithmic axis for scale. By comparison of CWT diagrams for healthy and for patient with LBBB it is easy to clearly identify the differences in time-frequency coefficients of ECG signals mentioned. Peaks of the CWT coefficients are in higher frequencies for healthy patients and in lower frequencies for patients with LBBB. By using ECG signal waveform and CWT of the same signal, simultaneously, it would be easier, for cardiologist, to confirm LBBB diagnosis, because the peaks can be read in frequency axis. Il. 4, bibl. 10 (in English; summaries in English, Russian and Lithuanian).

### **Синиша С. Илич. Обнаружение блокады ветви левого пучка при анализе непрерывной волновой трансформации ECG сигнала // Электроника и электротехника. – Каунас: Технология, 2007. – № 2(74). – С. 13–16.**

Рассмотрены волновые трансформации в сигнале электрокардиограммы QRS комплекса здорового пациента и пациента с блокадой ветви левого пучка. При анализе сигналов во времени и пространстве, употреблена непрерывная волновая трансформация (CWT) и Marlet волновая трансформация. Иллюстрируя результаты, CWT диаграмма чертится в прямой и логарифмической осях. При сравнении диаграмм здорового пациента с LBBB диаграммами, можно четко выделить изменения коэффициентов выше упомянутых сигналов электрокардиограмм. В случае здорового пациента максимальные значения наблюдаются в зоне высших частот нежели у пациентов в случае LBBB. Пользуясь электрокардиограммой и ее CWT одновременно, кардиологу проще диагностировать LBBB, так как максимальные значения можно наблюдать на частотной оси. Ил. 4, библи. 10 (на английском языке; рефераты на английском, русском и литовском яз.).

### **Siniša S. Ilić. Kairiojo pluošto atšakos blokados aptikimas analizuojant tolydžiąją ECG signalo banginę transformaciją // Elektronika ir elektrotechnika – Kaunas: Technologija, 2007. – Nr. 2(74). – P. 13–16.**

Pateikiamos sveiko paciento ir paciento, turinčio kairiojo pluošto atšakos blokadą (LBBB), QRS komplekso elektrokardiogramos signalo banginės transformacijos. Analizuojant signalus laiko ir dažnio erdvėje, naudojama tolydinė banginė transformacija (CWT) ir Marlet banginė transformacija. Iliustruojant rezultatus, CWT diagrama braižoma tiesinėje ir logaritminėje ašyse. Lyginant sveiko paciento ir paciento, turinčio LBBB, diagramas, galima aiškiai išskirti minėtųjų elektrokardiogramos signalų koeficientų pokyčius. CWT koeficientų maksimalios vertės sveiko paciento elektrokardiogramoje yra aukštesnių dažnių srityje nei pacientų, turinčių LBBB. Naudojantis elektrokardiograma ir jos CWT tuo pačiu metu, kardiologui paprasčiau diagnozuoti LBBB, nes maksimalias vertes galima aptikti dažnio ašyje. Il. 4, bibl. 10 (anglų kalba; santraukos anglų, rusų ir lietuvių k.).

DOI: 10.5755/j02.eie.10361